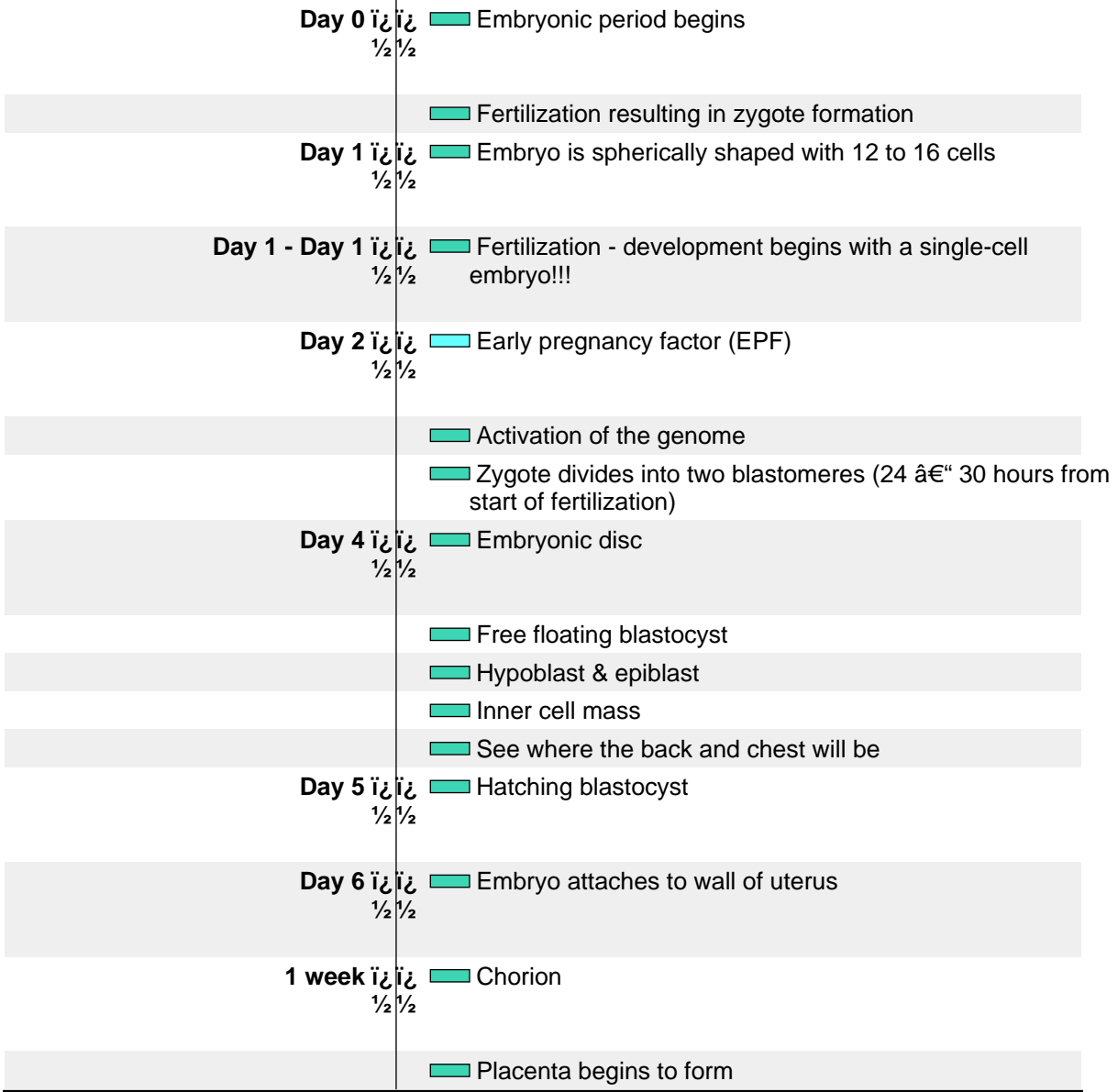


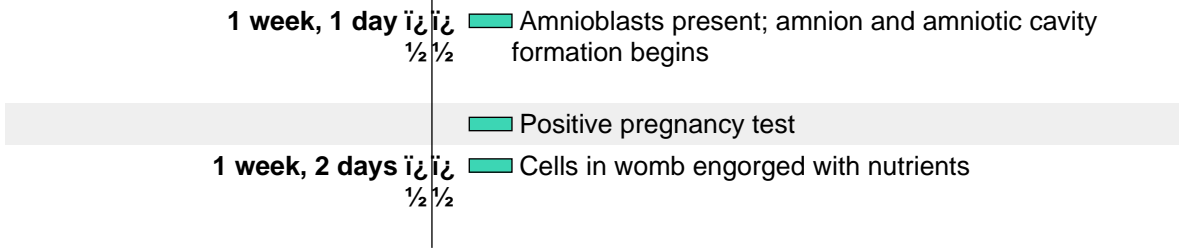
Prenatal Development Timeline

- | | | | |
|---|--|--|---|
| ■ Nervous | ■ Cardiovascular | ■ Muscular | ■ Early Events |
| ■ Special Senses | ■ Respiratory | ■ Skeletal | ■ Growth Parameters |
| ■ Blood & Immune | ■ Gastrointestinal | ■ Endocrine | ■ General |
| ■ Skin/Integument | ■ Renal/Urinary | ■ Reproductive | ■ Movement |








Unit 1: The First Week



Unit 2: 1 to 2 Weeks



1 week, 4 days $\frac{1}{2}$ $\frac{1}{2}$	Longitudinal axis
1 week, 5 days $\frac{1}{2}$ $\frac{1}{2}$	Implantation complete
	Yolk sac
1 week, 6 days $\frac{1}{2}$ $\frac{1}{2}$	Primordial blood vessels
	Amnion with single cell layer
	Chorionic villi
2 weeks $\frac{1}{2}$ $\frac{1}{2}$	Yolk sac
	Yolk sac
Unit 3: 2 to 3 Weeks	
2 weeks, 1 day $\frac{1}{2}$ $\frac{1}{2}$	3 germ layers
	Rostral-caudal orientation
2 weeks, 2 days $\frac{1}{2}$ $\frac{1}{2}$	Erythroblasts in yolk sac
	Three types of blood-forming cells in yolk sac
	Amnion with two cell layers
	Secondary villi
2 weeks, 4 days $\frac{1}{2}$ $\frac{1}{2}$	Foregut, midgut, and hindgut
	Brain is first organ to appear
	Neural plate induced by notochordal process
	Connecting stalk
2 weeks, 6 days $\frac{1}{2}$ $\frac{1}{2}$	Numerous blood islands in umbilical vesicle
	Foregut
	Stomodeum forming
	Beginnings of the heart can be seen
	Blood vessels emerge simultaneously in umbilical vesicle, embryo proper, amnion, and connecting stalk
	Dorsal aortae (paired)
	Paired tubular heart
	Forebrain, midbrain, and hindbrain
	Neural groove deepens substantially
	Three main divisions of brain
	Neural crest: Rostral and facial

<p>3 weeks   1/2 1/2</p>	<p> Blood and blood vessels</p>
<p>Unit 4: 3 to 4 Weeks</p>	
<p>3 weeks, 1 day   1/2 1/2</p>	<p> Midgut emerging</p>
	<p> Respiratory outgrowth</p>
	<p> Atria (right and left) far apart</p>
	<p> Circulatory system function begins</p>
	<p> Endocardial tubes fuse forming tubular heart</p>
	<p> Heart begins beating</p>
	<p> Pericardium</p>
	<p> Primary head vein</p>
	<p> Sinus venosus</p>
	<p> Tubular heart begins folding</p>
	<p> Umbilical arteries</p>
	<p> Umbilical veins (right and left)</p>
	<p> Neural tube</p>
	<p> Body cavities</p>
	<p> Hyoid arch</p>
<p>3 weeks, 3 days   1/2 1/2</p>	<p> Thyroid complete</p>
	<p> Cystic primordium</p>
	<p> Liver</p>
	<p> Membrane between future mouth and throat may begin to rupture</p>
	<p> Internal carotid arteries</p>
	<p> Neuropore (near brain) closes</p>
	<p> Notochord</p>
<p>3 weeks, 5 days   1/2 1/2</p>	<p> First part of pancreas</p>
	<p> Pharyngeal arch 3</p>
	<p> Lung bud</p>
	<p> Descending aorta</p>
	<p> Unidirectional circulation</p>
	<p> Brain involves 40% of neural tube</p>
	<p> Lowermost spinal cord formation begins</p>
	<p> Neural tube closes (lower back)</p>
	<p> Somites: Pairs 21 through 29</p>
	<p> Upper limb primordium at level of somites 8 to 10</p>
	<p> Progressively C-shaped embryo</p>
<p>4 weeks   1/2 1/2</p>	<p> Skin is so thin, you can see through it!</p>

	Esophagus primordia
	Intestines growing in length
	Pancreas: Ventral pancreas
	Pharynx
	Small & large intestines
	Bronchial buds
	Lungs begin filling chest cavity
	Trachea
	Circulatory system "well established"
	Functioning two-chamber heart
	Heart chambers bulging with fluid
	Heart now functions as two parallel pumps
	Heart rate (about) 113 beats/min
	Most cranial nerve ganglia
	Cerebellum
	Fourth ventricle
	Amnion surrounds embryo
	Limb buds - the first sign of arms and legs
	Lower limb buds
	Umbilical cord emerging
	Upper and lower limb buds

Unit 5: 4 to 5 Weeks

4 weeks, 3 days $\frac{1}{2}$ $\frac{1}{2}$	Early eyes
4 weeks, 3 days - 5 weeks $\frac{1}{2}$ $\frac{1}{2}$	Germ cells migrate to gonads
4 weeks, 4 days $\frac{1}{2}$ $\frac{1}{2}$	Lungs: Right and left primary (or main stem) bronchi
	Sinu-atrial (SA) node
	Eyes located on sides of head
	Lens pits
	Nose: Nasal pits
	Brain enlarges 50% since Carnegie Stage 13
	Brain: Cerebral hemispheres appear and begin rapid growth
	Brain: Lateral ventricles
	Hypothalamus
4 weeks, 5 days $\frac{1}{2}$ $\frac{1}{2}$	Caecum
	Blood vessels penetrate diencephalon
	Coronary arteries (terminal end)
	Optic chiasm
	Brain with five main sections

	<ul style="list-style-type: none"> First nerve fibers Most cranial nerves seen Synapses among motor neurons in spinal cord Third ventricle
5 weeks ½	<ul style="list-style-type: none"> ACTH [adrenocorticotropin hormone] Growth hormone Pituitary gland Limb buds form hand plates Permanent kidneys Bronchial tree branching accelerates Lobar pattern mimics adult pattern Pacemaker cells Head is one third of entire embryo

Unit 6: 5 to 6 Weeks

5 weeks, 1 day ½	<ul style="list-style-type: none"> Wrist joints are forming
5 weeks, 2 days ½	<ul style="list-style-type: none"> Thyroid detaches from pharynx Atrioventricular (AV) node Circle of Willis almost complete Cochlear nerve present Musculocutaneous, radial, ulna, and median nerves enter upper limb bud All cranial nerves identifiable
5½ weeks ½	<ul style="list-style-type: none"> Initial tooth formation
5½ weeks - 6 weeks ½	<ul style="list-style-type: none"> Subtle movement begins
5 weeks, 4 days ½	<ul style="list-style-type: none"> Cartilage formation
5 weeks, 5 days ½	<ul style="list-style-type: none"> Nerve cells differentiating
5 weeks, 5 days - 7 weeks, 1 day ½	<ul style="list-style-type: none"> Melanocytes in epidermis
5 weeks, 6 days ½	<ul style="list-style-type: none"> Cartilage in occipital sclerotomes (1-4) Primordial vermiform appendix All spinal nerves present Dura begins forming in basal area

	<ul style="list-style-type: none"> Frontal and temporal poles of cerebral hemispheres Somites: Pairs 38 and 39
	<ul style="list-style-type: none"> Synapses in spinal cord between interneurons and primary afferent neurons
6 weeks $\frac{1}{2}$ $\frac{1}{2}$	<ul style="list-style-type: none"> Face withdraws from light touch around mouth
	<ul style="list-style-type: none"> Blood forming in liver Nipples along side of trunk Adrenal glands Glucagon in pancreas
	<ul style="list-style-type: none"> Handplates develop subtle flattening Joints Tooth buds (primary teeth) Diaphragm is largely formed Intestines fill base of umbilical cord External ears Synapses form in spinal cord Crown-heel length 1.6 cm

Unit 7: 6 to 7 Weeks

6 weeks, 2 days $\frac{1}{2}$ $\frac{1}{2}$	<ul style="list-style-type: none"> Elbow regions sometimes identifiable
	<ul style="list-style-type: none"> Hands polygon-shaped Humerus, radius, and ulna Toe rays sometimes present Deltoid muscle Submandibular gland primordia Inferior vena cava Left coronary artery arises from aorta Optic fibers Eyelid folds sometimes present Brainwave activity has begun Cerebrospinal fluid production begins
6$\frac{1}{2}$ weeks $\frac{1}{2}$ $\frac{1}{2}$	<ul style="list-style-type: none"> The hands begin to move
	<ul style="list-style-type: none"> Volar pads on palms Bones first form in the collar bones and lower jaw
6 weeks, 5 days $\frac{1}{2}$ $\frac{1}{2}$	<ul style="list-style-type: none"> Beginnings of occipital and sphenoid bones
	<ul style="list-style-type: none"> Cartilaginous styloid process Limbs point forward (ventrally) Anal membrane Lung, left: Oblique fissure defines upper and lower lobes

	<ul style="list-style-type: none"> ■ Circulus arteriosus (Circle of Willis) complete ■ Right coronary artery arises from aorta ■ Tricuspid and mitral valves ■ Primitive nasal cavity ■ Eyelids: Upper and lower lids present and growing ■ Occipital pole of cerebral hemispheres
6 weeks, 6 days $\frac{1}{2}$ $\frac{1}{2}$	<ul style="list-style-type: none"> ■ Feet polygon-shaped ■ Cloacal membrane ruptures
7 weeks $\frac{1}{2}$ $\frac{1}{2}$	<ul style="list-style-type: none"> ■ Head rotates ■ Leg movements ■ B lymphocytes in liver ■ Ovaries ■ Testes begin to differentiate ■ Insulin in pancreas ■ Foot plates notched ■ Hiccups ■ Tendons attach muscle to bone ■ The heart has four chambers and is nearly complete. ■ The heart rate peaks at 165 to 170 beats per minute. ■ Crown-heel length 2.2 cm

Unit 8: 7 to 8 Weeks

7 weeks, 1 day $\frac{1}{2}$ $\frac{1}{2}$	<ul style="list-style-type: none"> ■ Upper limbs with slightly flexed elbows ■ Sacrocaudal spinal cord formation (secondary neurulation) complete
7 weeks, 1 day - 8 weeks $\frac{1}{2}$ $\frac{1}{2}$	<ul style="list-style-type: none"> ■ Stomach: Folds in stomach wall
7 weeks, 2 days $\frac{1}{2}$ $\frac{1}{2}$	<ul style="list-style-type: none"> ■ Arteries and veins of heart complete
7 weeks, 3 days $\frac{1}{2}$ $\frac{1}{2}$	<ul style="list-style-type: none"> ■ The knee joints have arrived ■ Wrists slightly flexed ■ Eyelids growing rapidly ■ Cerebral hemispheres cover more than half of diencephalon
7 $\frac{1}{2}$ weeks $\frac{1}{2}$ $\frac{1}{2}$	<ul style="list-style-type: none"> ■ Hands begin to touch face ■ The hands touch each other as do the feet! ■ Fingertips thicken

	<ul style="list-style-type: none"> Plantar pads toes EKG pattern similar to adult
7 weeks, 4 days $\frac{1}{2}$ $\frac{1}{2}$	<ul style="list-style-type: none"> The fingers are free
7 weeks, 5 days $\frac{1}{2}$ $\frac{1}{2}$	<ul style="list-style-type: none"> Bone-forming cells called osteoblasts emerge
	<ul style="list-style-type: none"> Hands can reach one another and fingers can overlap Brain: Internal capsule with connections to epithalamus, dorsal thalamus, and mesencephalon Cerebral hemispheres cover 75% of diencephalon Cortical plate expanding rapidly
7 weeks, 6 days $\frac{1}{2}$ $\frac{1}{2}$	<ul style="list-style-type: none"> The toes are free
8 weeks $\frac{1}{2}$ $\frac{1}{2}$	<ul style="list-style-type: none"> Complex response to touch More frequent hand-to-face contact Mouth opens & closes Squinting The embryo floats and rolls over in the womb Hairs first appear in eyebrows & around mouth Skin multi-layered, loses transparency Male embryos are making testosterone already! The embryo's joints are similar to adult joints Diaphragm complete Esophagus: Longitudinal muscles Urethra Urine production and release Peristalsis in large intestine Occasional breathing motions begin Blood supply to the brain closely resembles adult pattern Cranial nerve distribution mimics adult pattern Retina: Four of the ten adult layers present Tympanic membrane "The hindbrain "presents striking resemblance to that of the newborn." Brain represents 43% of embryo Grey and white matter Right- and left-handedness emerges Crown-heel length 4.3 cm Embryo contains approximately 1 billion (10⁹) cells Embryonic Period Ends The 8-week embryo has formed more than 4,000 permanent body parts.

Unit 9: 8 to 9 Weeks

8½ weeks	Eyelids completely fused
9 weeks	Neurons synapse in cerebral cortex (marginal zone)
	Bends hip & knee if sole of foot touched
	Drinking fluid is becoming routine
	Sucking the thumb
	The young fetus now sighs, stretches, moves the head, opens the mouth, and moves the tongue
	Tongue movement
	Female fetuses have early reproductive cells in their ovaries
	Thyroid gland weighs 2 grams
	Small intestine peristalsis
	Face, hands, and feet sense light touch

Unit 10: 9 to 10 Weeks

9 weeks - 10 weeks	Early vocal cords
	My weight will rise more than 75% this week
9½ weeks	I yawn when I want
9 weeks, 4 days	Yawns
10 weeks	Eyes roll downward reflexively
	Palatine tonsils
	Fingernails and toenails begin to grow!
	Three-layered epidermis
	Tiny unique fingerprints have arrived!
	Now, all the bones are getting harder
	Tooth buds (secondary teeth)
	Glomeruli formation begins
	Physiologic herniation ends
	Corpus callosum begins
	Crown-heel length 7.5 cm

Unit 11: 10 to 11 Weeks

10 weeks - 12 weeks	Langerhans cells enter epidermis
10½ weeks	Volar and plantar pads regress

11 weeks $\frac{1}{2}$ $\frac{1}{2}$	<ul style="list-style-type: none"> ■ The face now makes complex expressions ■ Immunological competence ■ Intermediate layer ■ Nose & lips completely formed ■ Now you can tell if your baby is a girl or a boy! ■ Thyroid gland weighs 12 grams ■ Intestines absorb water & glucose ■ Auditory cells: inner & outer hair cells □ Crown-heel length
---	--

Unit 12: 11 to 12 Weeks

11 weeks - 12 weeks $\frac{1}{2}$ $\frac{1}{2}$	□ Weight increases by 60% this week
--	--

12 weeks $\frac{1}{2}$ $\frac{1}{2}$	<ul style="list-style-type: none"> ■ Hands touch the mouth up to 50 times per hour ■ T lymphocytes leave thymus ■ Many different hormones are present in pituitary gland ■ Thyroid gland produces hormone ■ Palate fuses ■ Upper limbs reach final proportion ■ Bladder resembles smooth muscle ■ Bowel movements ■ Liver: Bile production begins ■ There are taste buds all over the mouth ■ Corpus callosum □ Crown-heel length 12 cm □ Head circumference 10 cm
---	--

Unit 13: 3 to 4 Months

13 weeks $\frac{1}{2}$ $\frac{1}{2}$	<ul style="list-style-type: none"> ■ Teeth are growing ■ Cilia lining airways ■ Most of body sensitive to touch □ Crown-heel length 15 cm
---	--

14 weeks $\frac{1}{2}$ $\frac{1}{2}$	<ul style="list-style-type: none"> ■ Girls move their jaws more than the boys do ■ Light touch to mouth evokes turn toward stimulus ■ 4-lobed cerebral cortex ■ Cerebellum resembles adult structure □ Crown-heel length 17 cm □ Fat deposits in cheeks
---	---

15 weeks $\frac{1}{2}$ $\frac{1}{2}$	<ul style="list-style-type: none"> Stem cells arrive in bone marrow
	<ul style="list-style-type: none"> Body fat emerges throughout the body
	<ul style="list-style-type: none"> Glucagon in fetal bloodstream
	<ul style="list-style-type: none"> Digestive enzymes
	<ul style="list-style-type: none"> Crown-heel length 19.5 cm
16 weeks $\frac{1}{2}$ $\frac{1}{2}$	<ul style="list-style-type: none"> Quickening
	<ul style="list-style-type: none"> Fat deposits upper & lower limbs
	<ul style="list-style-type: none"> Tooth enamel
	<ul style="list-style-type: none"> Bronchial tree nearly complete
	<ul style="list-style-type: none"> Hormonal stress response to invasive procedures
	<ul style="list-style-type: none"> Crown-heel length 21 cm

Unit 14: 4 to 5 Months

17 weeks $\frac{1}{2}$ $\frac{1}{2}$	<ul style="list-style-type: none"> Retina has discrete layers
18 weeks $\frac{1}{2}$ $\frac{1}{2}$	<ul style="list-style-type: none"> Cream-like substance protects skin
	<ul style="list-style-type: none"> Sweat glands
	<ul style="list-style-type: none"> Insulin secretion
	<ul style="list-style-type: none"> Speaking motion of larynx
	<ul style="list-style-type: none"> Corpus callosum complete
19 weeks $\frac{1}{2}$ $\frac{1}{2}$	<ul style="list-style-type: none"> Melanin production
	<ul style="list-style-type: none"> Number of oogonia peak (at about 7 million) within fetal ovaries
	<ul style="list-style-type: none"> Daily cycles in biological rhythms
20 weeks $\frac{1}{2}$ $\frac{1}{2}$	<ul style="list-style-type: none"> All skin layers and structures
	<ul style="list-style-type: none"> Surfactant production (low levels)
	<ul style="list-style-type: none"> Hearing and responding to sound begins
	<ul style="list-style-type: none"> Hearing and responding to sound begins
	<ul style="list-style-type: none"> Crown-heel length 28 cm
	<ul style="list-style-type: none"> Head circumference 20 cm

Unit 15: 5 to 6 Months

20 weeks - 24 weeks $\frac{1}{2}$ $\frac{1}{2}$	<ul style="list-style-type: none"> Eyelids separate, eyes open and close
21 weeks $\frac{1}{2}$ $\frac{1}{2}$	<ul style="list-style-type: none"> Stratum corneum

21 weeks - 22 weeks ½ ½	□ If born prematurely from this point on, survival is possible
22 weeks ½ ½	■ Cornea structure
	■ Behavioral states
23 weeks ½ ½	□ Brain weight 100 grams
24 weeks ½ ½	■ Blink-startle response; females before males
	□ Crown-heel length 34.5 cm


Unit 16: 6 to 7 Months


25 weeks ½ ½	■ Intestinal lining contains all adult cell types
	■ Rods & cones
	■ The ability to taste
26 weeks ½ ½	■ Additional fat deposits decrease wrinkles
	■ Tear production
	■ The ability to smell has arrived
26 weeks - 38 weeks ½ ½	■ Brain weight increases 400% to 500%
27 weeks ½ ½	■ Pupils react to light
28 weeks ½ ½	■ Distinguishes sounds of different frequencies
	□ Crown-heel length 39.5 cm


Unit 17: 7 to 8 Months


30 weeks ½ ½	■ Breathing motions are common even though there is no air in the womb
	■ 6-layered cerebral cortex
	□ Head circumference 30 cm
32 weeks ½ ½	■ Esophagus: Lower esophagus muscles functional
	■ Glomeruli formation complete
	■ Alveoli
	■ Memory - music preferences
	□ Crown-heel length 45 cm


Unit 18: 8 to 9 Months

32 weeks - 36 weeks  Prenatal food affects newborn taste preferences
 $\frac{1}{2}$ $\frac{1}{2}$


34 weeks  Rapid weight gain
 $\frac{1}{2}$ $\frac{1}{2}$

35 weeks  Firm grip
 $\frac{1}{2}$ $\frac{1}{2}$


 Amniotic fluid volume peaks


36 weeks  Surfactant production accelerates
 $\frac{1}{2}$ $\frac{1}{2}$


 Brain weight 300 grams


 Crown-heel length 48.5 cm


Unit 19: 9 Months to Birth


37 weeks  Fetus drinks an estimated 15 oz (or 450cc) of amniotic fluid/day
 $\frac{1}{2}$ $\frac{1}{2}$

38 weeks  Air breathing begins
 $\frac{1}{2}$ $\frac{1}{2}$


 By term, the typical umbilical cord measures 20 to 24 inches (50 to 60 cm)

 Heart beats 54 million times before birth


 Major circulatory changes


 Spinal cord ends at third lumbar vertebrae

 Brain weight 350 grams

 Crown-heel length 50 cm

 Fetus initiates labor

 Head circumference 35 cm

 Time to be born!